



CASE REPORT

Open Access

'The intraabdominal bleeding with an inguinal defect that mimicking a femoral vein aneurysm'. A case report

Bülent Kaya*, Orhan Bat, Nuriye Esenbulut and Kemal Memisoglu

Abstract

Inguinal hernia repair is commonly performed operation in surgical practice. Thirty-five years old female patient was operated with the diagnosis of inguinal hernia. The inguinal defect was misdiagnosed as femoral vein aneurysm in surgical exploration. The postoperative diagnostic imaging revealed that the inguinal defect had been confused as femoral vein aneurysm due to intra-abdominal hemorrhagic fluid after an ovarian cyst rupture.

Background

Inguinal hernia repair is one of the most commonly performed operation in surgical practice. Sometimes, challenging cases may be encountered. An inguinal hernia can mimic many pathologies and become a surgical dilemma, even for the skilled surgeon [1]. The correct diagnosis of an inguinal mass is important in order to avoid performing non-therapeutic surgery and serious complications.

We reported a patient who had been explored with the diagnosis of inguinal hernia. The defect was diagnosed as femoral vein aneurysm in surgical exploration. The postoperative diagnostic imaging revealed that the inguinal defect had been confused as femoral vein aneurysm due to intra-abdominal hemorrhagic fluid after an ovarian cyst rupture. We concluded that an inguinal mass can be a diagnostic dilemma with treatment problems.

Case Presentation

Thirty-five years old female patient presented with pain and swelling in her left inguinal region. She was very thin in appearance. On physical examination, an inguinal mass, bulging with coughing about 3 × 4 cm in diameter was palpated. She had been operated for left ovarian cyst rupture about 8 years ago. She was diagnosed as inguinal hernia and prepared for elective inguinal hernia

repair. The routine preoperative laboratory tests were within normal limits.

The inguinal canal was explored in operation. A lump, bluish-purple in color, about 3 × 4 cm in diameter was detected (Figure 1). It was emerging from the inferior part of the inguinal canal. It was accepted as a vascular lesion with its appearance. The cardiovascular surgeon was invited for consultation. The dissection was performed up to the conjoint tendon and iliopubic tract. It was decided that the lesion was a femoral vein aneurysm and elective surgery should be recommended.

We performed pelvic ultrasonography (USG) and pelvic Magnetic Resonance Imaging (MRI) postoperatively. Two ovarian cysts about 2.5 × 3.5 cm and 3 × 2.5 cm in diameter were detected in left ovary. There was also free hemorrhagic fluid in lower abdominal quadrants (Figure 2). The tumor markers including AFP, CEA, CA 125, CA 15-3 and CA 19-9 were within normal limits. The color doppler USG of inguino-femoral region was normal. There were no femoral arterial aneurysm in MRI angiography (Figure 3). The intra-abdominal hemorrhagic fluid had been mimicked the venous aneurysm. The patient was decided to followed-up and elective hernia repair was recommended.

Many surgical pathologies may present as inguinal swelling such as hernia, lymphadenopathy, varices, and endometriosis [2,3] Sometimes it is difficult to diagnose an inguinal mass definitively even in surgical exploration. Preoperative or intraoperative correct diagnosis is mandatory for performing a proper management.

* Correspondence: drbkaya@yahoo.com

Fatih Sultan Mehmet Training and Research Hospital, Department of General Surgery Istanbul-Turkey

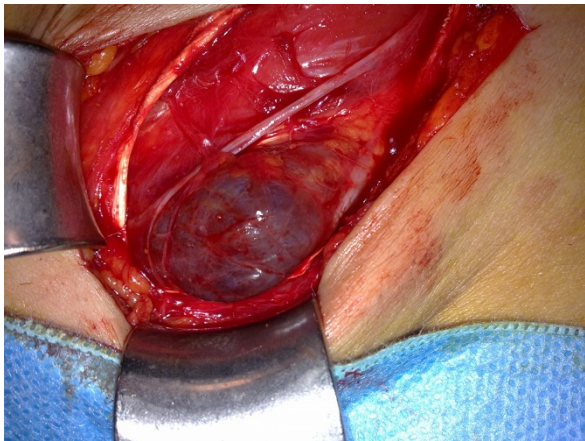

Figure 1 Inguinal image that mimics a venous aneurysm.

A venous aneurysm is usually defined as a venous dilation which communicates with a main venous structure by a channel. It may cause serious complications such as deep vein thrombosis and pulmonary emboli [4]. Venous aneurysms can be seen in every major veins and may be misdiagnosed as an inguinal hernia [5]. Femoral vein aneurysm is a rare clinical pathology [6]. It may also be misdiagnosed as an inguinal or femoral hernia. Castaldo ET, have been presented a femoral vein aneurysm simulating an inguinal hernia and added that

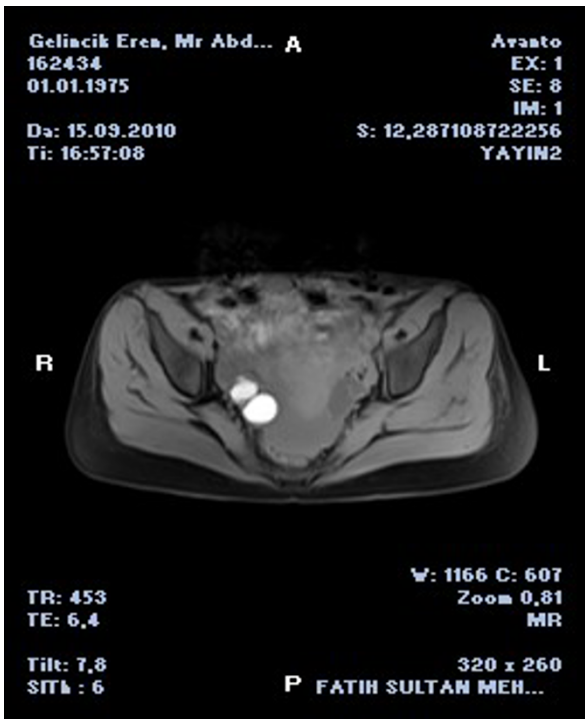

Figure 2 Hemorrhagic fluid was detected in MRI.

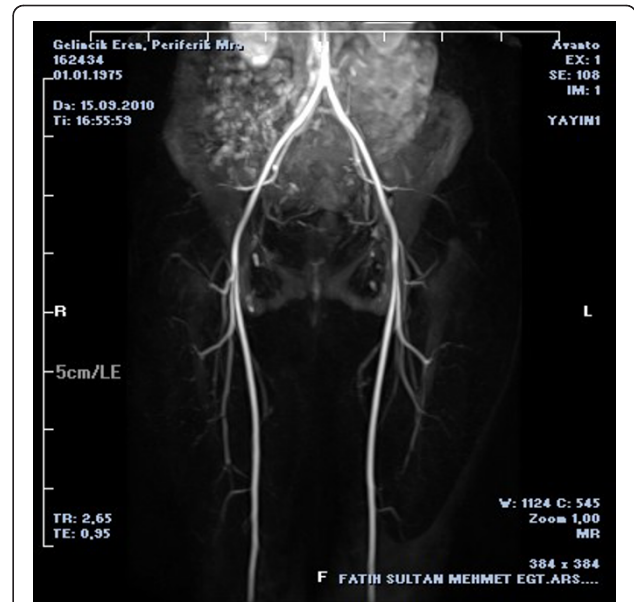


Figure 3 Peripheral MR Angiography was normal.

only five cases have been reported in literature before their case report [7]. On the other hand, an inguinal hernia, mimicking a venous aneurysm is even more rare clinical condition. To our knowledge, there is no such a case that was reported in English literature up to date. Our patient was presented with classical findings of inguinal hernia. She had a bulging inguinal mass enlarging with increase in intra-abdominal pressure. The appearance of lump was confusing at operation. After exploration with blunt dissections, the lesion was diagnosed as femoral vein aneurysm intra-operatively. The surgical intervention was terminated. An elective aneurysm repair after diagnostic evaluation was planned.

The postoperative diagnostic evaluation was performed. The arterial and venous system was imaged with MRI angiography and color doppler ultrasonography. There were no aneurysm in both femoral artery or vein. The only detected pathology was ovarian cysts with intra-abdominal hemorrhagic fluid in pelvic MRI. Marcucci G recommended doppler USG for venous aneurysms in inguinal region and lower extremities [8]. The bulging lesion that had been diagnosed as femoral vein aneurysm was a peritoneal sac (inguinal defect) filled with hemorrhagic fluid.

Conclusion

It is also important to conclude that although it is very rare, an inguinal defect with an intra abdominal bleeding can mimic a vascular lesion like venous aneurysm. The definitive diagnosis of inguinal mass is mandatory for proper treatment. Radiological evaluation of inguinal mass before surgery can gain clinical importance.

Consent

Written informed consent was obtained from the patients for publication of this case report and accompanying images. A copy of the written consents is available for review by the Editor-in-Chief of this journal.

Authors' contributions

BK, OB, NE, KM were involved in the direct care of the patient. In addition, BK was responsible for drafting the manuscript and OB, NE and KM helped to draft the manuscript. All authors have read and approved the final manuscript.

Competing interests

The authors declare that they have no competing interests.

Received: 21 December 2010 Accepted: 17 April 2011

Published: 17 April 2011

References

1. Rutkow IM, Robbins AW: Demographic, classificatory, and socioeconomic aspects of hernia repair in the United States. *Surg Clin North Am* 1993, **73**:413-426.
2. Chi C, Taylor A, Munjuluri N, Abdul-Kadir R: A diagnostic dilemma: round ligament varicosities in pregnancy. *Acta Obstet Gynecol Scand* 2005, **84**:1126-1127.
3. Oh SN, Jung SE, Rha SE, Lim GY, Ku YM, Byun JY, Lee JM: Sonography of various cystic masses of the female groin. *J Ultrasound Med* 2007, **26**:1735-1742.
4. Gillespie DL, Villavicencio JL, Gallagher C, Chang A, Hamelink JK, Fiala LA, O'Donnell SD, Jackson MR, Pikoulis E, Rich NM: Presentation and management of venous aneurysms. *J Vasc Surg* 1997, **26**:845-852.
5. Majeski J: Surgical repair of primary saphenous vein aneurysm of the proximal leg after initial presentation as an inguinal hernia. *Am Surg* 2002, **68**:999-1002.
6. Pandey V, Wolfe JH: Superficial femoral vein aneurysm with massive pulmonary embolism. *J R Soc Med* 2003, **96**:460-1.
7. Castaldo ET, Williams EH, Dattilo J, Passman M, Naslund T, Guzman RJ: Common femoral vein aneurysm simulating an inguinal hernia. *Am Surg* 2005, **71**:591-4.
8. Marcucci G, Accrocca F, Antignani PL, Siani A: An isolated aneurysm of the thigh anterolateral branch of the greater saphenous vein in a young patient presenting as an inguinal hernia. *Interact Cardiovasc Thorac Surg* 2010, **10**:654-5.

doi:10.1186/1755-7682-4-13

Cite this article as: Kaya *et al.*: 'The intraabdominal bleeding with an inguinal defect that mimicking a femoral vein aneurysm'. A case report. *International Archives of Medicine* 2011 **4**:13.

Submit your next manuscript to BioMed Central
and take full advantage of:

- Convenient online submission
- Thorough peer review
- No space constraints or color figure charges
- Immediate publication on acceptance
- Inclusion in PubMed, CAS, Scopus and Google Scholar
- Research which is freely available for redistribution

Submit your manuscript at
www.biomedcentral.com/submit

